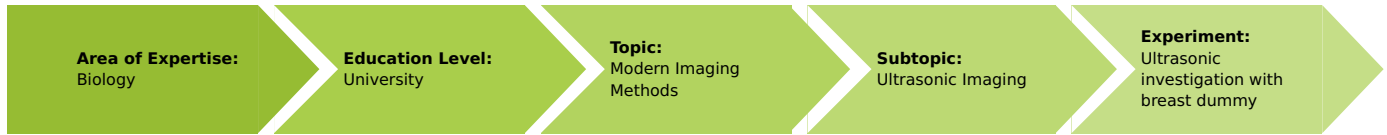


Ultrasonic investigation with breast dummy

(Item No.: P5950300)

Curricular Relevance



Difficulty



Difficult

Preparation Time



10 Minutes

Execution Time



1 Hour

Recommended Group Size



2 Students

Additional Requirements:

- PC (Windows)

Experiment Variations:

Keywords:

Breast sonography, Tumour size, Benign tumour, Ultrasound imaging procedures, Ultrasound echography, A-mode, B-mode

Overview

Principle

This experiment shows a typical application of ultrasounds in medical diagnostics. On a realistic breast dummy a benign tumour has to be diagnosed, localized and measured with an ultrasound cross section imaging method.

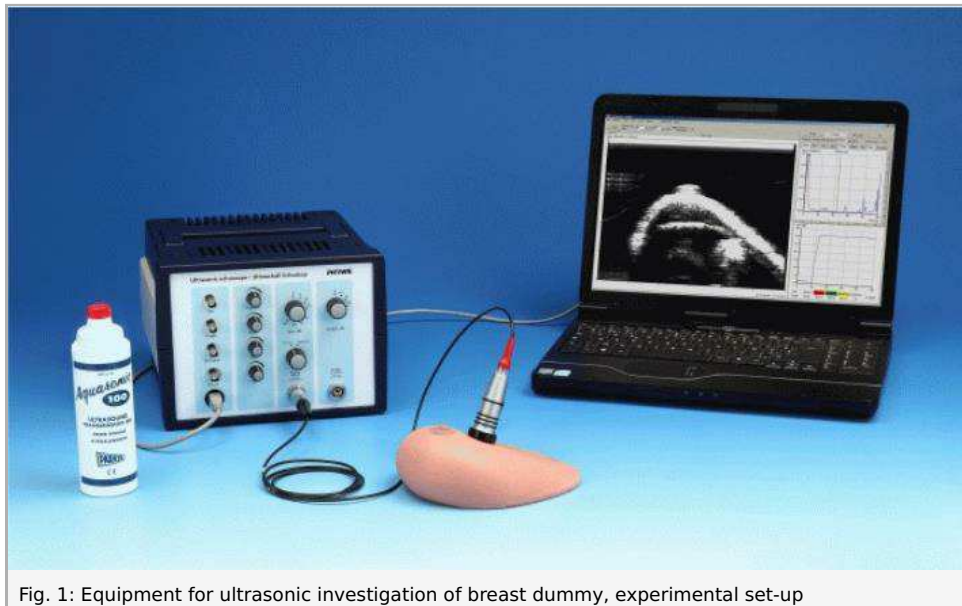


Fig. 1: Equipment for ultrasonic investigation of breast dummy, experimental set-up

Equipment

Position No.	Material	Order No.	Quantity
1	Basic Set Ultrasonic echoscope II	13924-99	1
2	Extension Set: Medical Ultrasonic Diagnostics	13921-04	1

Basic Set Ultrasonic echoscope II consisting of:

- 1x Ultrasonic echoscope
- 1x Ultrasonic probe 1 MHz
- 1x Ultrasonic probe 2 MHz
- 1x Ultrasonic test block
- 1x Ultrasonic cylinder set
- 1x Ultrasonic test plates
- 1x Ultrasonic gel
- 1x Echoscropy software (for Windows)

Extension set: medical ultrasonic diagnostics consisting of:

- 1x simplified heart dummy for echocardiography
- 1x breast dummy
- 1x eye dummy

Tasks

1. Examine the breast dummy and search for any pathological changes. Try to characterize them as accurately as possible (size, location, mobility, strength of the change).
2. Produce an ultrasonic B-scan image of the breast dummy, especially in the regions of interest. Based on the ultrasound image, estimate the location and magnitude of the tumour.

Safety information

Caution!

This is not a medical device. Do not use for examination of human bodies. Consult the special operation and safety instructions included in the user manual of the ultrasonic echoscope.

Set-up and procedure

- Put the breast dummy in front of you on the table.
- Palpate the dummy with the flat of your hand and your fingers. Start with soft pressure, to palpate the surface. Increase the pressure continuously to examine also deeper layers of the breast dummy. With this method you will locate two swellings close to the nipple.
- Next, examine the two regions using the ultrasonic probes.
- Connect the 1 MHz probe to the "Probe (Reflection)" plug.
- Switch the selection knob to "Reflection".
- Select medium gain and output power.
- Switch on the echoscope.
- Start up the measure Ultra Echo software in A-scan mode.
- Set the ultrasound velocity to 1300 m/s for the dummy (For human tissues, the normal sound velocity would be 1540 m/s). Toggle from Time to Depth scale.
- Couple the probe to the test dummy using sufficient coupling gel. Scan the region of interest determined by palpating.
- The measure Ultra Echo software shows the reflected wave as a peak. Adjust the transmitter and receiver amplifier settings until the upper and bottom side of the tumour and the back wall echo can clearly be detected. (Fig.2). The peak shape can be optimised adjusting the time-TGC (Time Gain Control) parameters.

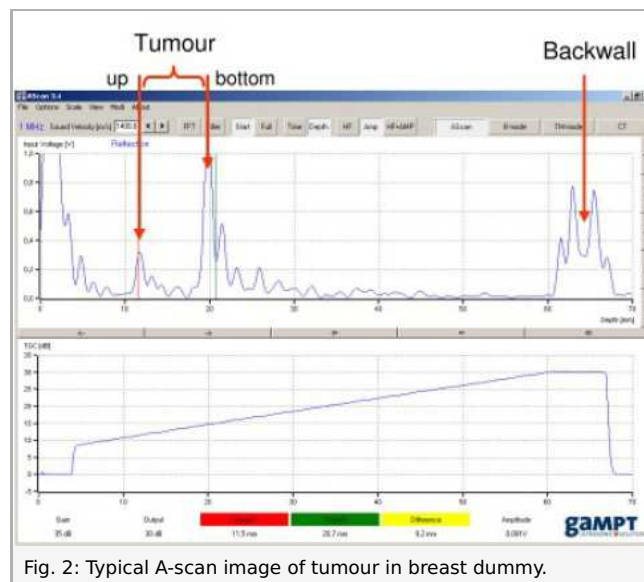


Fig. 2: Typical A-scan image of tumour in breast dummy.

- Keep the settings and toggle to B-scan mode.
- Perform some linear scans in the two tumour regions. The ultrasound probe is scanned uniformly, with plenty of coupling gel and light pressure over the surface of the breast model. Several images should be taken in different scan directions to determine an optimal scanning path. Recording an ultrasound image with sufficient contrast of all objects of interest requires some practice. If necessary, the device settings can be varied to achieve better image quality.
- Too strong pressure applied to the probe leads to tissue deformations and induces incorrect results.
- Estimate the location and size of the tumour.

Software

The measure Ultra Echo software records, displays and evaluates the data transferred from the echoscope. After starting the program the measure mode is active and the main screen "A-Scan mode" is open. All actions and evaluations can be selected and started in this window.

The main screen shows in the upper part the A-scan signal, the frequency of the connected transducer, the mode (reflection/transmission). Actual positions of cursors (red and green line) are displayed at the bottom of the window. The cursors can be positioned by mouse click. The time of flight is displayed under the cursor buttons.

Note

The breast dummy and the probes should be cleaned immediately after use with water or a normal detergent. Dried residues of ultrasonic gel are hard to remove. If necessary use a soft brush. Never use alcohol or liquids with solvents to clean the dummy or

the probes.

Evaluation and result

Evaluation

Ultrasound is an imaging test that sends high-frequency sound waves through your breast and converts the reflected waves into images on a viewing screen. The ultrasound technician places a sound-emitting probe on the breast to conduct the test. There is no radiation involved

Mammography and sonography are the standard imaging techniques for detection and evaluation of breast disease. Mammography is the most established screening modality. Especially in young women and women with dense breasts, sonography appears superior to mammography, and differentiation between solid tumours and cysts is easier. Sensitivity and specificity of sonography or mammography are higher if sonography and mammography are combined.

Ultrasound is not used on its own as a screening test for breast cancer. Rather, it is used to complement other screening tests. If an abnormality is seen on mammography or felt by physical exam, ultrasound is the best way to find out if the abnormality is solid (such as a benign fibroadenoma or cancer) or fluid-filled (such as a benign cyst). It cannot determine whether a solid lump is cancerous, nor can it detect calcifications.

But doctors can use ultrasound to guide biopsy needles precisely to suspicious areas in the breast.

If you are under age 30, your doctor may recommend ultrasound before mammography to evaluate a palpable breast lump (a breast lump that can be felt through the skin). Mammograms can be difficult to interpret in young women because their breasts tend to be dense and full of milk glands. (Older women's breasts tend to be fattier and are easier to evaluate). In mammograms, this glandular tissue looks dense and white — much like a cancerous tumour. Some doctors say that locating an abnormality in the midst of dense gland tissue can be like finding a polar bear in a snowstorm. Most breast lumps in young women are benign cysts, or clumps of normal glandular tissue.

To interpret the A-scan curves and B-scan images, some physics basics have to be considered.

An echoscope generates, with help of a piezoelectric ceramic, a short pulsed mechanical wave. If this wave is coupled into solid state material it propagates in a linear way, perpendicular to the emitting piezo and will be reflected on interfaces with acoustic impedance changes (boundaries).

From the measured time of flight (t) and a known sound velocity (c), the distance (s), between the ultrasonic probe and the boundary of a solid can be determined for perpendicular sound incidence, in the following way:

In reflection mode

$$s = \frac{c \cdot t}{2} \quad (1)$$

From a geometrical point of view, the detected signals come always from the direction perpendicular to the probe surface. As the surface of the dummy (Fig. 4) is not a horizontal flat surface, the image is not a real cross section image of the breast dummy but gives a deformed image. Press only slightly the probe on the surface of the dummy. Do not deform the surface; the probe should look in a different direction than normal perpendicular direction.

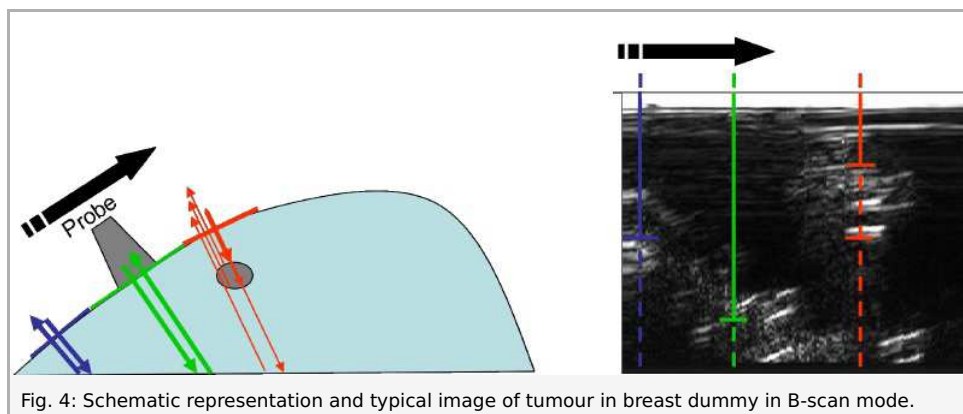


Fig. 4: Schematic representation and typical image of tumour in breast dummy in B-scan mode.

Without a scanner, only dept measurements give significant results. For lateral information the beam must be mechanically or electronically scanned over the area of interest. The most clinical ultrasound equipment use phase array electronic scanning method. The probe is fixed and the ultrasound beam scans the object by varying the incident angle.

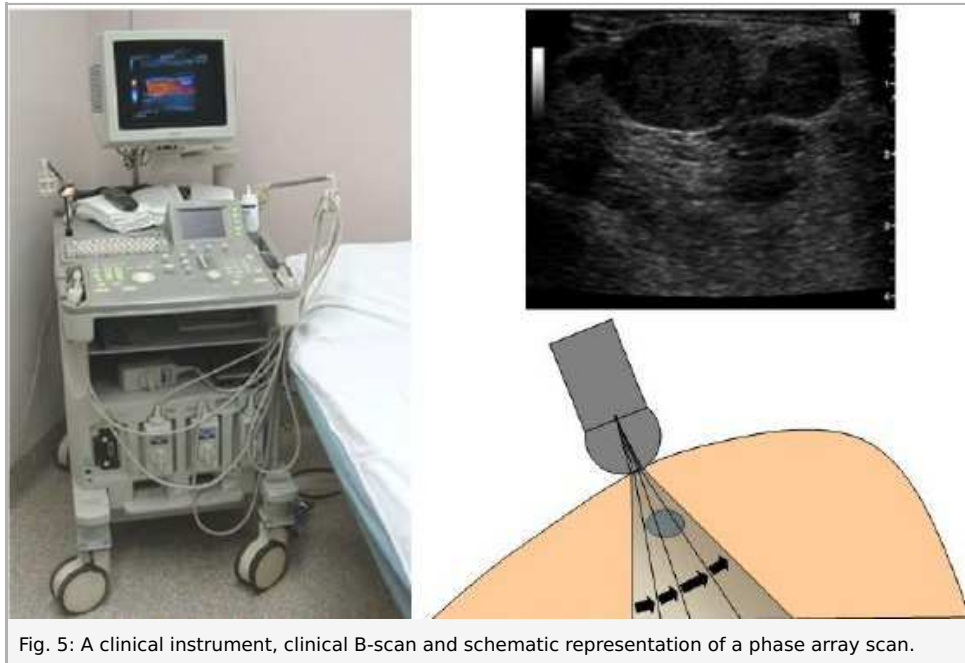


Fig. 5: A clinical instrument, clinical B-scan and schematic representation of a phase array scan.

Results

Tumour 1

The tumour was located by palpation at 2 cm at the right of the nipple. It is located near the surface and has about a diameter of about 1–3 cm. The tumour can be easily moved in the tissue.

The sonographic image (Fig. 6) shows the tumour region along a scan line from top to bottom of the breast passing at the right side of the nipple (Fig. 7). The tumour is located 10 mm below the surface and has an axial expansion of 24 mm. The lateral

extent can not be accurately determined from the ultrasound image, as it is a hand guided B-mode image. The “continuous” line at the bottom of the screen comes from the back wall echo of the breast dummy. Due to the higher absorption of the tumour, a clear acoustic shadow appears in the wall echo of the breast dummy.

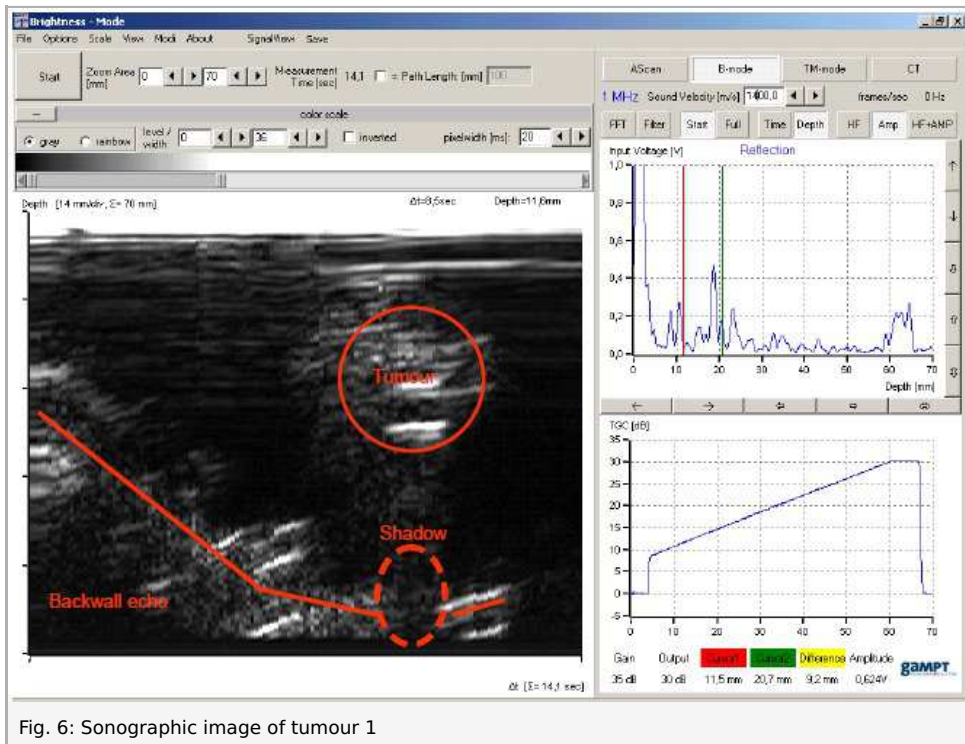


Fig. 6: Sonographic image of tumour 1

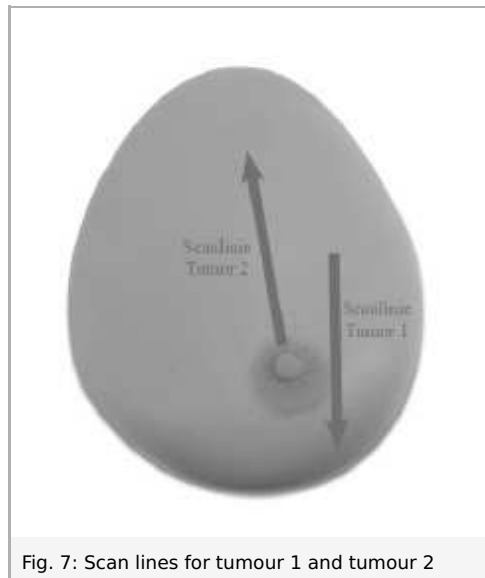


Fig. 7: Scan lines for tumour 1 and tumour 2

Tumour 2

The 2nd tumour was located approximately 5 cm above the nipple. It shows similar properties to palpation as the 1st tumour.

The sonographic image (Fig. 8) was taken along a line starting just above the nipple and going straight up (Fig. 7). The tumour is also located at a depth of 10 mm and has a length of about 26 mm. The tumour has an oval shape with a slightly inclined axis. Similar to tumour 1, the increased absorption of tumour tissue, causes an acoustic shadow on the back wall echo. The reflected signal, on the lower right corner, is a multiple echoes of the back wall. This is an artefact and has non importance for diagnostics.

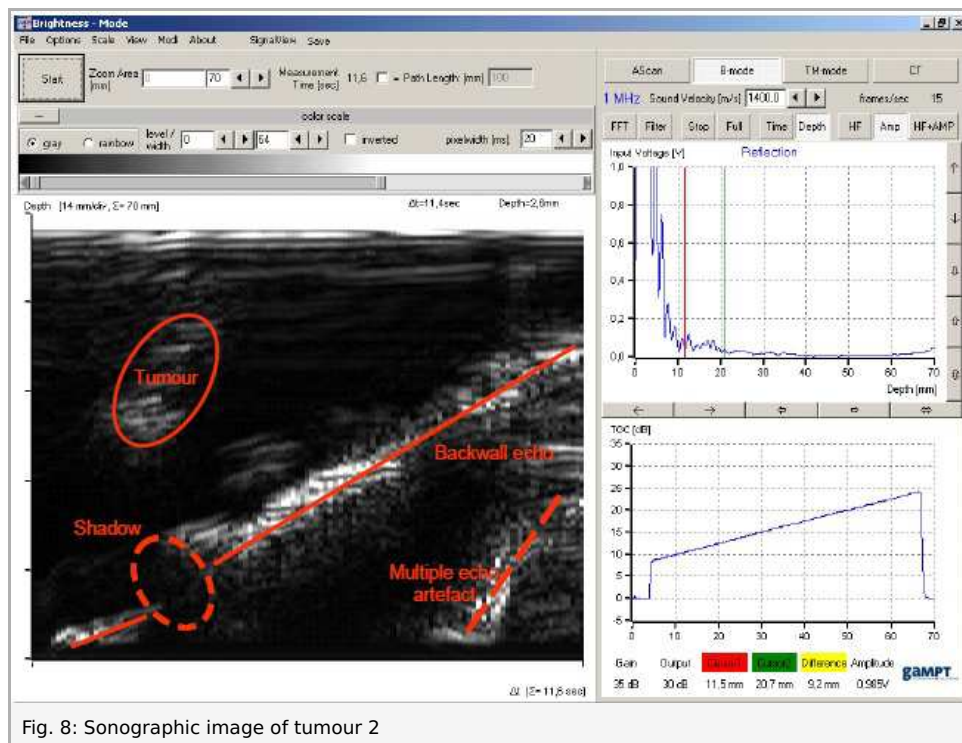


Fig. 8: Sonographic image of tumour 2